



Myasthenia Gravis with Caries Spine: An Anaesthetist's Perspective

¹Dr Geeta Ahlawat, MBBS, MD (Anaesthesia), DNB, Professor, Department of Anaesthesiology, Pt.B.D.S. PGIMS, Rohtak, Haryana, India.

²Dr Sumedha Vashishth*, MBBS, MD (Anaesthesia), Senior Resident, Department of Anaesthesiology, Pt.B.D.S. PGIMS, Rohtak, Haryana, India.

³Dr Jitendra Wadhvani, MBBS, MS (Orthopaedics), Assistant Professor, Department of Orthopaedics, Pt.B.D.S. PGIMS, Rohtak, Haryana, India.

⁴Dr Vikas Saroha, MBBS, MS (General Surgery), DNB (CTS), Medical officer, Department of Cardiothoracic Surgery, Pt.B.D.S. PGIMS, Rohtak, Haryana, India.

Corresponding Author: Dr Sumedha Vashishth*, MBBS, MD (Anaesthesia), Senior Resident, Department of Anaesthesiology, Pt .B.D.S. PGIMS, Rohtak, Haryana, India.

Type of Publication: Case Report

Conflicts of Interest: Nil

Abstract

Myasthenia Gravis (MG) is an autoimmune disease of neuromuscular junction. It is characterized by weakness and fatigability of skeletal muscles. Tuberculosis (TB) being an infectious disease may exacerbate MG, resulting in higher complication and morbidity. Patients with MG receive immunosuppressive therapy exposing them to higher risk of TB. Anaesthesia and surgery in MG is associated with high risk to life and severe complications. The risk is mainly due to higher sensitivity to neuromuscular blocking agents (NMBAs). We bring forth the anaesthetic management and challenges in a known case of MG suffering TB lumbar spine planned for surgical decompression of lumbar spine. MG patients require special attention and individualized management in preparation for surgery, with close monitoring along with proper selection of anaesthetic agents. Surgery and

anaesthesia in such patients are always high risk with complications scaling up to death.

Key-Words: Myasthenia Gravis, Tuberculosis, Neuromuscular Blocking Agents, Immunosuppressive Therapy.

Introduction

Myasthenia Gravis (MG) is an autoimmune disease of neuromuscular junction.^[1] Disease is characterized by weakness and fatigability of skeletal muscles which increases after exercise and usually subsides after periods of rest, typically after taking anticholinesterase medication.^[2] The pathomechanism of MG is associated with formation of autoantibodies against nicotinic acetylcholine receptors on post-synaptic membrane of neuromuscular junction.^[2]

Tuberculosis (TB) being an infectious disease may exacerbate MG; resulting in higher complication and morbidity.^[3] Patients with MG receive

immunosuppressive therapy exposing them to higher risk of TB. Concurrent treatment of TB and MG creates many challenges to treatment like drug reactions, toxicity, and high pill burden leading to non compliance.

Anaesthesia and surgery in MG is associated with high risk to life and severe complications. The risk is mainly due to higher sensitivity to neuromuscular blocking agents (NMBAs) even in periods of complete remission.^[4] The relationship between MG and TB has not been determined and has been shown only in some case reports that too with pulmonary TB.^[3, 5, 6] We therefore bring forth a rare case report of anaesthetic management in a patient of MG associated with TB of lumbar spine (extrapulmonary) planned for surgical decompression and stabilization of spine.

Case Report

A 56 years old male patient, presented with complaints of pain in back and radiating to leg since six months. MRI of lumbosacral spine was suggestive of TB of spine at L3-L4 region (Fig 1-2). Therefore patient was put on ATT (Category I) and was scheduled for decompression and stabilization L3- L4 region of spine.

History of the patient revealed that he was suffering from MG since last 30 years and had undergone thymectomy for the same 30 years ago (Fig 3). Patient gave history of steroid ingestion for many years and has left the same since last one year. He was taking Azathioprine 50 mg OD since last one year. On examination, patient had bilateral weakness of lower limbs (right>left). Sensory and bowel-bladder functions were intact. Bulbar and respiratory symptoms were absent.

Patient was scheduled for surgery under general anaesthesia (GA). Informed and written consent was taken for postoperative ventilatory support requirement. Premedication was done with tablet ranitidine 150 mg and tablet alprazolam a day and 2 hours before surgery. Baseline Heart rate 96 bpm, Blood pressure 132/86 mmHg

and SpO₂ 97% on room air and respiratory rate was 18 cycles/ min. Preoxygenation was done with 100% oxygen for 3 min. Induction was done with injection glycopyrrolate 0.2 mg/IV, injection fentanyl 100 µg/IV and injection propofol 140 mg/ IV, after checking ventilation injection vecuronium 6 mg/IV was given, patient was then ventilated for 3 minutes and airway was secured with reinforced cuffed endotracheal tube (ETT) of size 8 mm.

Anaesthesia was maintained with oxygen : nitrous (50:50), 1% sevoflurane and intermittent boluses of injection vecuronium 1mg/IV with neuromuscular blockade monitoring using train of four (TOF) nerve stimulator. Surgery was performed in prone position with free abdomen. Hypotensive anaesthesia was used to improve the surgical field and decrease the blood loss during surgery. Intraoperatively 1500ml ringer lactate, 500ml hydroxy ethyl starch (HES) and one unit packed cell were transfused. Injection tranexamic acid 1 gm was given intravenously to reduce blood loss during surgery. Surgery lasted for three hour with urine output of 500 ml and blood loss of up to 1000 ml (Fig 4).

After surgery, patient was made supine and adequacy of reversal was confirmed with TOF peripheral nerve stimulator. Neuromuscular blockade was reversed with injection glycopyrrolate 4mg/IV and injection neostigmine 2.5mg/IV. ETT was removed when patient was awake and obeying commands.

Discussion

MG patients require special attention and individualized management in preparation for surgery, with close monitoring along with proper selection of anaesthetic agents.^[4] Surgery and anaesthesia in such patients are always high risk with complications scaling up to death.^[4] These patients may also require prolonged ventilation in ICU settings.^[5,7]

Patients with MG are resistant to neuromuscular blockade with depolarising NMBAs (succinylcholine) because they have decrease number of acetylcholine receptors.^[8] Commonly there are two approaches to administer GA in these patients-

- i) with non-depolarising NMBAs
- ii) without non-depolarising NMBAs.

The use of fentanyl-propofol combination, fentanyl-sevoflurane combination, has been reported in literature.^[9]

In this case we administered GA using fentanyl-propofol combination with non-depolarising NMBAs. Sensitivity to non-depolarising NMBAs are variable in patients with MG. Neuromuscular monitoring is essential during GA to avoid prolong neuromuscular blockade in these patients.

The NMBAs of choice in these patients are rocuronium, vecuronium and cis-atracurium of which we used vecuronium as it is easily available in our institute. We measured the degree of neuromuscular blockade using quantitative TOF nerve stimulator throughout the surgery. We used short-acting anaesthetics and multimodal analgesia to minimize opioid side effects and avoided medications known to interfere with neuromuscular transmission. Variability and unpredictability of reversal with neostigmine is well known. However, we used neostigmine for reversal of non-depolarising NMBAs in our patients because firstly, our patient was not taking any anticholinesterase medications and secondly, non availability of sugamadex in our institute.

Our patient was on immunosuppressive drug (Azathoprine), which might have predisposed our patient for developing extrapulmonary TB. GA ensuring complete airway protection with intubation of trachea, is the preferred technique, in view of anticipated respiratory problems with use of muscle relaxants in these patients. This problem was further dealt with use of rapidly metabolizing drugs like fentanyl, propofol and sevoflurane. Continuous neuromuscular monitoring along

with all other monitoring helped us to maintain our patient within safe limits, while using non-depolarising NMBAs. Systolic blood pressure was not allowed to exceed 100 mmHg to avoid blood loss. Thus, we successfully managed the anaesthetic challenges of a known case of MG with TB with uneventful intraoperative and postoperative complications. The best way of preparing such a patient for surgical procedure is to recognize and understand both, medical condition and co-existing disease and anaesthetic management should be individualized with thorough analysis and proper planning for judicious choice of relaxant, anaesthetic agents and careful perioperative neuromuscular monitoring.

References

1. Drachman DB. 1994. Myasthenia gravis. *N Engl J Med.* 330: 1797–1810.
2. Conti-Fine BM, Milani M and Kaminski HJ. 2006. Myasthenia gravis: past, present, and future. *J Clin Invest.* 116(11): 2843-54.
3. Nam TS, Park MS, Choi KH, Jung HJ, Yoon GJ, Choi SM et al. 2010. Myasthenia gravis aggravated by steroid-induced isolated mediastinal tuberculous lymphadenitis. *J Clin Neurol.* 6: 224–226.
4. Dillon FX. 2004. Anesthesia issues in the perioperative management of myasthenia gravis. *Semin Neurol.* 24: 83–94.
5. Goldberg W M, Brewin T B. 1962. A case of thymoma, myasthenia gravis and disseminated tuberculosis. *Can Med Assoc J.* 86: 492–495.
6. Furui E, Ide Y, Takamori M. 1995. Acute deterioration of myasthenia gravis in association with tuberculous mediastinal lymphadenitis, simulating recurrence of thymoma. A case report. *Rinsho Shinkeigaku.* 35: 428–430.
7. Heliopoulos I, Patlakas G, Vadikolias K, Artemis N, Kleopa KA, Maltezos E et al. 2003. Maximal

voluntary ventilation in myasthenia gravis. Muscle Nerve. 27: 715–719.

8. Eisenkraft JB, Book WJ, Mann SM, Papatostas AE, Hubbard M. 1988. Resistance to succinylcholine in myasthenia gravis: a dose response study. Anesthesiology 69: 760-763.
9. Lin CC, Chen MF, Chen HM, Tan PP, Shyr MH. 1996. Propofol anaesthesia in a patient with myasthenia gravis- a case report. Acta Anaesthesiol Sin. 34: 89-92.

Figure and Legends

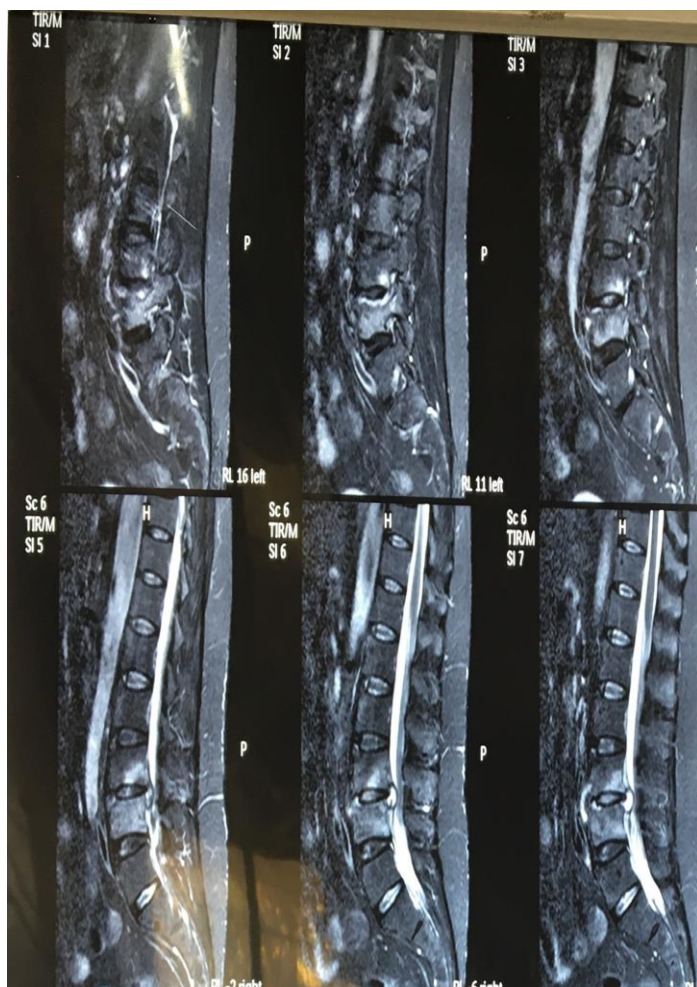


Fig 1: Sagittal section MRI of 56 year old male showing lumbosacral region of spine with destruction of L3 and L4 vertebral region because of Tuberculosis.

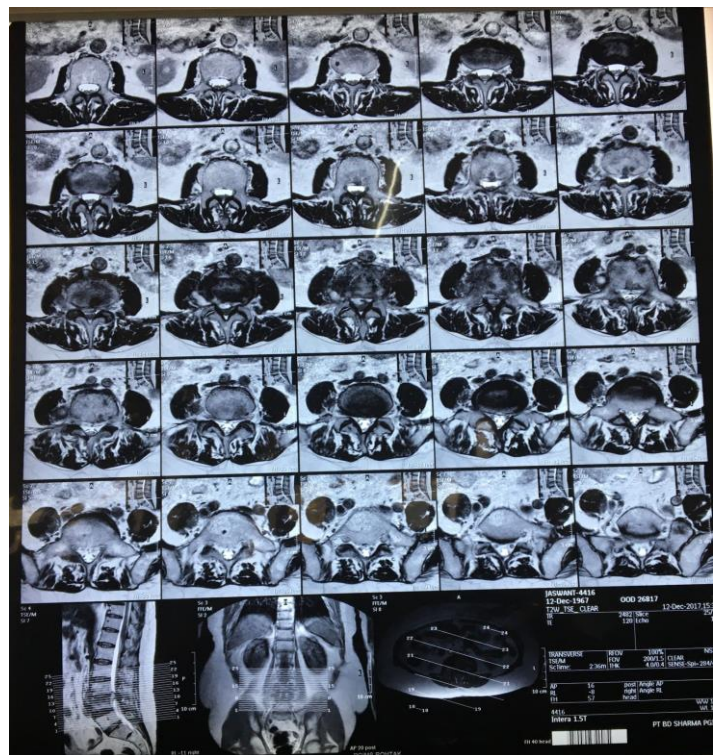


Fig 2: Axial section MRI of the same patient showing the destruction of L3-L4 vertebral level because of tuberculosis.

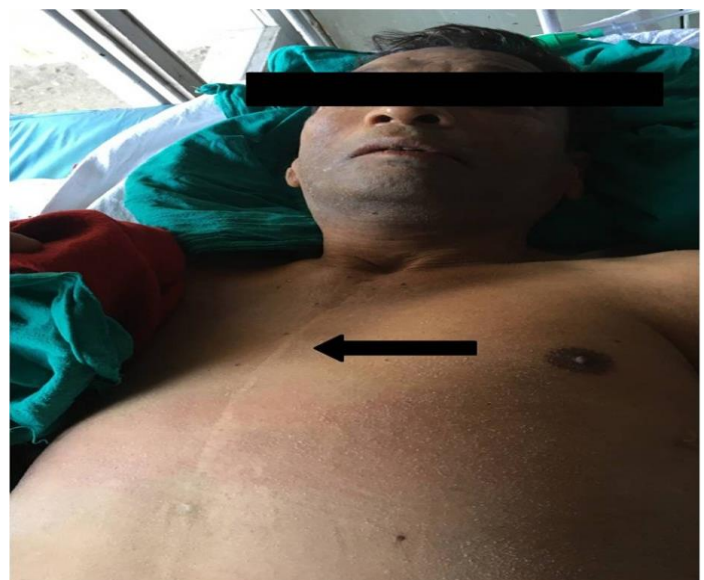

Fig 3: Clinical photograph of patient showing midline surgical scar of thymectomy done 30 years ago.

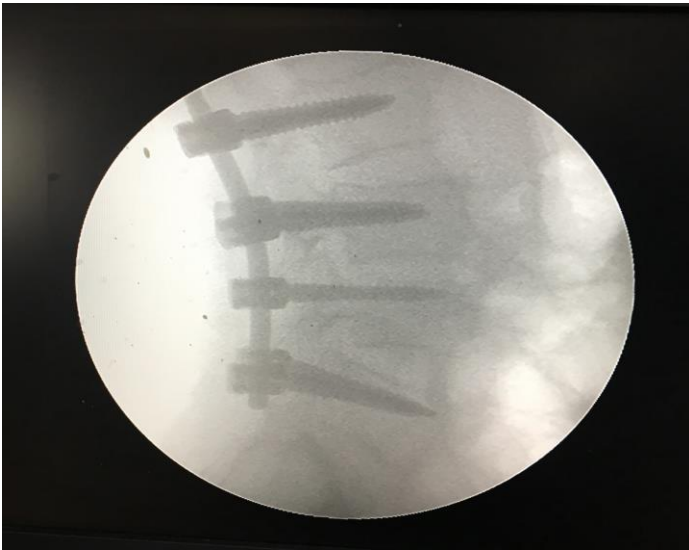

Fig 4: Intra operative fluoroscopic image of lumbosacral spine after decompression and posterior instrumentation.

- **Source of support:** Facilities available in our government tertiary institute “Pt B D S PGIMS”, Rohtak, Haryana, India. No other financial funding.
- **Conflict of Interest:** The authors declare that there is no conflict of interests regarding the publication of this paper in view of financial and other relationships.
- **Consent:** Informed consent was taken from the patient regarding the procedure and publication of material in relation to the disease of the patient.