

Enigmatic appearances of Squamous cell carcinoma of the gingival and buccal mucosa: a case report series & review

¹Dr. Venkatesh Balaji Hange, Postgraduate Student, K. D. Dental College & Hospital, Mathura-281006, Uttarpradesh.

²Dr. Shishir Mohan Garg, Head of the department, K.D. Dental College & Hospital, Mathura-281006, Uttarpradesh.

³Dr. Sourav Majhi. Postgraduate Student, K.D. Dental College & Hospital, Mathura-281006, Uttarpradesh.

Corresponding Author: Dr. Venkatesh Balaji Hange, Postgraduate Student, K. D. Dental College & Hospital, Mathura-281006, Uttarpradesh.

Citation this Article: Dr. Venkatesh Balaji Hange, Dr. Shishir Mohan Garg, Dr. Sourav Majhi, “Enigmatic appearances of Squamous cell carcinoma of the gingival and buccal mucosa: a case report series & review”, IJMSIR- December - 2020, Vol – 5, Issue - 6, P. No. 34 – 42.

Type of Publication: Case Report

Conflicts of Interest: Nil

Introduction

Squamous cell carcinoma (SCC) of oral cavity is one of the common worldwide malignancies and ranked number 5 cause for cancer deaths in males. It is also the most frequent malignant tumor of the oral cavity. It accounts for about 90% of all oral malignancies.(1) The most widespread sites of incidence are the latero-ventral surface of the tongue, floor of the mouth and buccal mucosa, less common location includes the gingiva.(2)

The general presentation of Squamous cell carcinoma described as an ulcerative/ulcero-proliferative growth which does not shows signs of healing. But the Squamous cell carcinoma of the oral cavity can show variable appearance sometimes mimicking inflammatory periodontal lesion, endoperiodontal lesion , dentoalveolar abscess , cervico-facial actinomycosis ,gingival polyp ,aphthous ulcer, pyogenic granuloma, gingivitis and benign hyperplasias of the gingiva etc. mentioned in current literature.

The group of gingival squamous cell carcinomas (GSCC) responsible for 6.3% among all oral carcinomas within 36 and 65 years of age and up to 91.4% in patients aged beyond 66 years. It comprises of 10% of total confirmed squamous cell carcinoma of oral cavity. (3)

Squamous cell carcinoma involving buccal mucosa is one of the infrequent clinical phenomenon, responsible for around 10% of all oral cancers in the United States. Buccal squamous cell cancer is locally aggressive, with recurrence rates of 30% to 80%.The poorer prognosis and elevated recurrence rate of Squamous cell carcinoma of buccal mucosa may be linked to a fact that, little or no resistance to tumour invasion occurs into the buccal space, through the buccinator muscle. This creates high tendency for lymphatic spread through the rich lymphatic drainage to the jugulodigastric, submental and submandibular lymph nodes. (4-5)

OSCC of the gingiva more often involves the mandible than the maxilla and is mostly seen in females over 50

years of age. OSCC of the gingiva is often asymptomatic as it is insidious in onset, and initially it can present as an intraoral mass or swelling and ulceration.(6) Due to close proximity to the dentition ,the early stage Gingival SCC is often diagnosed as benign inflammatory condition related to dentition. This often results in poor prognosis.

Present article enlightens the malignant Squamous cell carcinoma (SCC) rare variable appearance mimicking common dental conditions . We report two cases of gingival SCC & one SCC of buccal mucosa. These cases show a aide memoire to keep the likelihood of carcinoma in mind when examining & making diagnosis of oral cavity conditions.

Keywords: Differential Diagnosis, Oral Cavity Cancer, Lower Lip Cancer, Gingival Carcinoma, Mimicking Lesion, Squamous Cell Carcinoma.

Case Report

Case 1: A 14 years old female patient of arrived to the department of oral and maxillofacial surgery at K.D Dental college & Hospital at Mathura, with chief problem of painless swelling and bleeding from gingiva which gradually increased to present size within last 6 months. The history given by the patient was tenderness, which was mild to moderate with continuous in nature for which she undergone excision treatment 1month back in private clinic. The condition reappeared despite treatment obtained. On clinical examination, revealed the lesion was round (Fig.1) circular gingival swelling, soft in consistency in the upper right quadrant of mouth. The swelling was 1.5 *4 cm roughly in size with ill defined margins & borders, ulcerated surface with myriad tiny bleeding points. No h/o deleterious habits, family history unremarkable.The provisional diagnosis was given. Pre surgical blood investigations were done and found within normal

range but, HPV test done using p16 staining showing patchy pattern suggestive of HPV. Chest X ray was clear, I.O.P.A.R., O.P.G. did not reveal significant bone loss (Fig.),bone. The differential diagnosis included Peripheral Giant Cell Granuloma ,verruciform Xanthoma, peripheral ossifying fibroma, and squamous cell carcinoma. As there was neoplastic potential of the lesion excisional biopsy was planned. Intra-operatively,the associated teeth # 12 ,13, 14, 15 and bone were also removed along with the gingival growth for histopathological examination under general anaesthesia. Healing was found to be unsatisfactory. Histopathological report revealed SCC of Gingiva (anterior upper right quadrant).

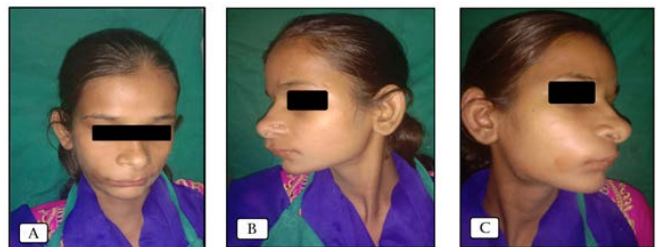

Fig. 1: A, B, C Shows pre operative profile photograph with obvious facial asymmetry on right side of the face between base of the nose and upper lip.

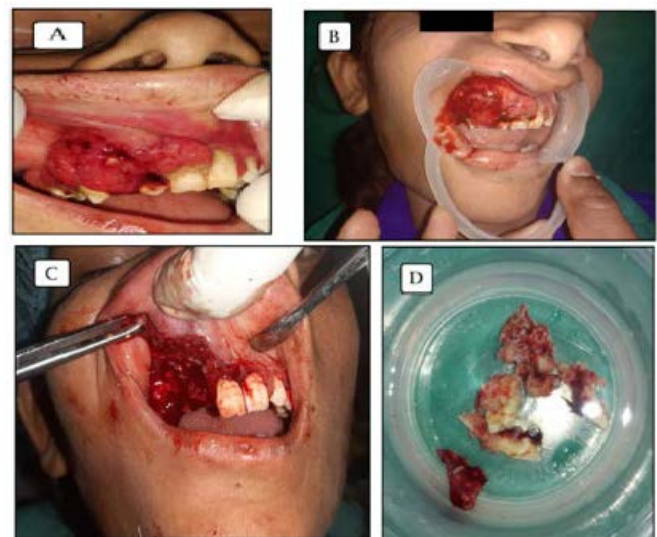


Fig.2 A) Shows round circular gingival swelling with lobulated appearance. B) Bleeding from tiny bleeding

points was evident during palpation examination of the swelling. C) Diagnostic Excisional biopsy was done ,with removal of involved teeth and bone from the affected site, along with gingival growth.

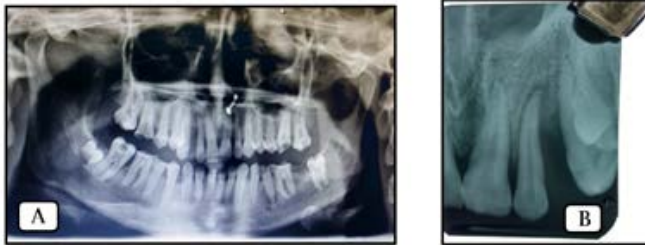

Fig. 3: A) Orthopantomogram does not shows any radiographic anomaly. B) Periapical view. Shows no destructive lesion was reported, except for horizontal alveolar bone loss between 12 & 13.

After final diagnosis of Squamous cell carcinoma (SCC) of gingival was made. Patient undergone unilateral maxillectomy with modified radical neck dissection. Maxillary reconstruction was made using free vascular fibula graft for the purpose of receiving implants for dental rehabilitation at later stage.

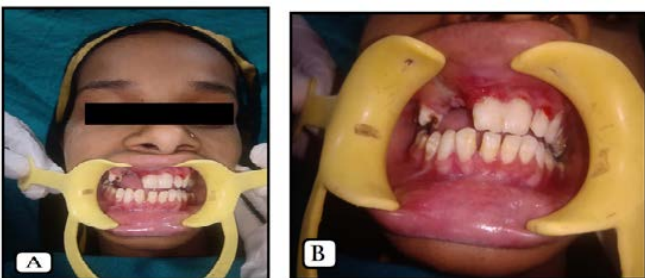


Fig. 4: A & B: Shows incomplete healing with appearance of neoplasm growth occurring in adjacent teeth revealed malignant potential of the lesion.

Case 2: A 52 years old male patient, reported to the department of oral and maxillofacial surgery at K.D Dental college & hospital, Mathura with chief complaints of non healing ulceration since last 6 months as well as non healed extraction socket in the mouth since last 6 months. The history given by the patient revealed that he was chronic smoker with

tobacco chewing habit approximately last 30 years, where he used to smoke 4-5 cigarettes /day. Patient stopped all the habits since 2 years. The patient observed a small growth which is continuously increasing in size since 6 months. The growth was seen on mucosa in the lower left posterior back tooth region. Patient visited the private dental clinic some 2 months back, where patient undergone excision along with extraction of teeth from the affected site. The growth reappeared again on the same region for which patient visited our department. On clinically palpation, tenderness was seen on the retro molar region with bleeding from ulcerated site. sub mandibular lymph nodes were palpable. The radiographic examination was done using OPG, which clearly showed radiolucency from the distal aspect of #46 extending to the retromolar trigone, involving inferior alveolar canal. The provisional diagnosis of chronic osteomyelitis was made. Complete blood investigations were requested which the revealed findings within normal range, except for slight elevation of erythrocytic sedimentation level. Based on the case history, clinical & radiographic examination an incisional biopsy was planned under general anaesthesia, where both hard and soft tissue specimen were collected and sent for histopathological examination. The operated site closed by primary closure with 3-0 silk but during follow up it was seen that healing was unsatisfactory, which clearly shows the sign of neoplastic activity. Finally the histopathological report revealed the final diagnosis as well differentiated squamous cell carcinoma. After final diagnosis of Squamous cell carcinoma (SCC) of gingival was made. Patient undergone hemi mandibulectomy with modified radical neck dissection. Reconstruction of mandible was achieved using free

vascular fibula graft for the purpose of receiving implants for dental rehabilitation at later stage.

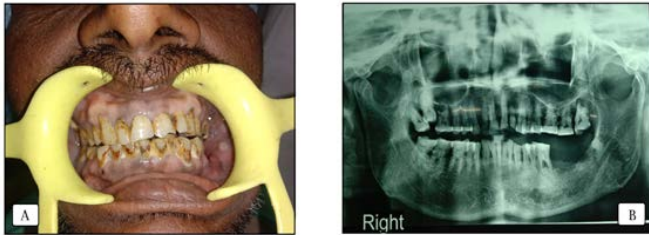

Fig. 5: A) Pre operative occlusion photograph shows gingival recession, tobacco stains, loss of gingival stippling. B) Orthopantomogram shows radiolucency from distal aspect of # 46 which extends retro-molar trigone. the radiolucency also involves inferior alveolar nerve canal.

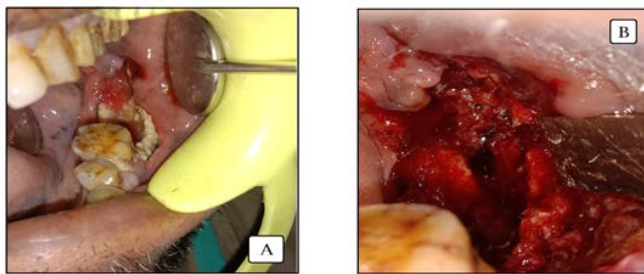


Fig.6: A) preoperative intraoral view showing bleeding ulcerative gingival margin along with exposed greyish yellow bone. B) During incision biopsy unhealed extraction socket exposed inferior alveolar nerve due to destruction of alveolar bone.

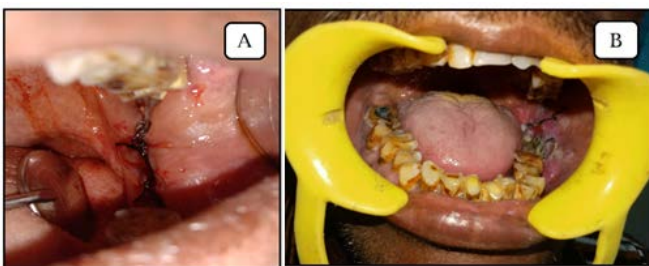


Fig. 7: A) primary closure done using horizontal mattress suture at the operated site. B) Post operative 1 week follow up showing ulceration again causing failure of primary closure.

Case 3: A male patient aged 55 years reported with chief complaints of growth over the lower lip region

which was proliferating in nature since 2-3 months. The patient gave history of tobacco chewing since 18 years with chronic alcoholic. He also gave history of holding the tobacco quid in the buccal vestibule. The patient had undergone extraction of proclined maxillary anterior tooth some 3 weeks back as it was assumed to be the cause of creating traumatic swelling on the lower lip in the private dental clinic 2 months back. Sub mandibular lymph nodes were palpable on the right side of the face. On clinical observation it was found that the growth was roughly round, smooth, erythematous, elevated swelling of 2*1.2 cm in size with white cheesy material expulsion. Patient also had grade II OSMF with bilaterally fibrotic bands extending to retromolar trigone. The lesion mimicked a benign soft tissue growth; hence provisional diagnosis of Traumatic Fibroma was made. Patient blood investigations were done, which was found to be normal within range, so an excisional biopsy was planned and done under local anaesthesia. The proliferative growth was excised and sent for histopathological examination. Operated site received primary closure and patient recalled after 1 week, where healing was found to be unsatisfactory. The histopathological report confirmed the final diagnosis as squamous cell carcinoma of the lip. So after confirmation of SCC, the patient underwent wedge resection followed by supra-omohyoid neck dissection under general anaesthesia and reconstruction done using advancement of the edge defect and re-approximation of muscles followed by the mucosa. The patient kept on follow-up.

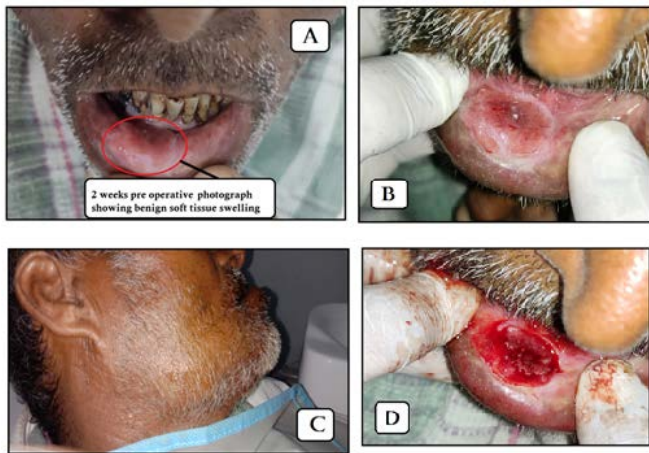


Fig. 8: A) 2weeks pre-operative photograph showing benign painless, non-tender gradually growing soft tissue swelling over labial mucosa of lower lip. B) During examination upon palpation white cheesy material was coming out from the swollen labial mucosa along with erythematous appearance. C) Palpable sub mandibular lymph nodes D) Operated site after excision of potentially malignant growth.

Discussion

One of the distinguishing features of the gingival SCC is its deviation in the clinical appearance when compared with the squamous cell carcinoma of other regions in the oral cavity. Gingival SCC is usually devoid of pain and the most frequent site for such tumor is the posterior mandible region.(7)

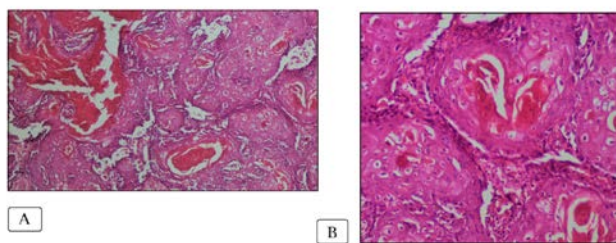


Fig. 9: A) High power photomicrograph presenting nests of malignant squamous epithelial cells occurring from epidermis and reach into the dermis. Indicating invasive squamous cell carcinoma. B) Photomicrograph presenting hyperchromatism, altered nuclear cytoplasm

ratio, atypical mitosis, dyskeratotic cells (H&E stain, x100).

Similarly, one of our cases, clinically the tumor was misjudged as pyogenic granuloma situated in maxillary anterior region where as in other case it was assumed to be a case of chronic osteomyelitis of posterior mandible region. All these case finally diagnosed as gingival squamous cell carcinoma after histopathological information. Presence of gingival SCC in maxillary anterior region is rare phenomenon, which further enhances enigmatic potential of squamous cell carcinoma of Gingiva. An initial presentation similar to harmless erythematous growing lesion with a smooth surface which mimics dentoalveolar abscess, Gingival polyp, apthous ulcer, pyogenic granuloma, gingivitis and gingival benign hyperplasias.

Pediatric OSCC is a rare phenomenon and may represent a diagnostic and treatment challenge. Oral squamous cell carcinoma predominantly affects individuals over 40 years old and is extremely rare in patients under 20 years of age.(8) In the Case 1, age of the female patient was 14 years which makes difficulty in actual diagnosis of the lesion.

The exact etiology responsible for Oral squamous cell carcinoma is unknown till now; but alcohol intake, betel nut chewing and smoking can be believed as compelling causative factors in adults. But recent literature shows that only (50%) gingival SCC which is contrary to the earlier review literature. (9-11)

The etiology and pathogenesis of pediatric OSCC considered different from OSCC in adult patients. Because of significantly little or no exposure to classical etiological risk factors causing OSCC. In young patients Genetic predisposition syndromes is predominant etiological risk factors of SCC. Most common genetic predisposition syndromes found in

pediatric OSCC includes Fanconi Anemia, Xeroderma Pigmentosum and Dyskeratosis Congenita.(12)

There are certain less common risk factors associated with etiology and pathogenesis of OSCC .These include polyvinyl chloride (found in plastics), Epstein-Barr virus and human papilloma virus. Malnutrition may be the causative factor in the development of OSCC when factors such as hepatic disease, pulmonary diseases are ruled out. (13-14)

In our case 2 & 3 smoking, betel nut chewing along with regular alcohol intake was a possible etiological risk factors where as in case 1 human papilloma virus infection & Anemia were risk factors. This explains varying etiology and pathogenesis of OSCC creates challenges in diagnosis as well as treatment of squamous cell carcinoma.

Squamous cell carcinoma of the buccal mucosa is a locally aggressive neoplasm of the oral cavity, even though modern enhancement in diagnosis and treatment survival rate has stayed around 50 per cent over the last two decades. Buccal mucosa cancer is one of the most common oral cancers reported in India. It occurs more predominantly in males than females and is associated with tobacco and alcohol use. Mucosal changes, such as leukoplakia and erythroplasia, are recurrent clinical findings. Frequent presenting symptoms include a buccal mass with pain and ulceration, predominantly alongside the occlusal plane. (15) The anatomy of the buccal mucosa and buccal space allows for extension of carcinoma unhindered by any anatomic barriers to neighboring intraoral sub sites and structures. The sub site of the oral cavity is classified as the mucosal lining of the cheeks and lips from the oral commissure anteriorly to the pterygomandibular raphe posteriorly in addition with the alveolar ridges superiorly and inferiorly. Deep tumor invasion through the buccinators

muscle into the buccal space often offers little resistance. As a result of this there is a high tendency for lymphatic spread through the rich lymphatic drainage to the jugulodigastric, submental and submandibular lymph nodes. (16-17)

In Case 3 the neoplastic growth was located over lower lip region which was proliferating in nature. The lower lip lesion is a part of oral cavity sub site which is in accordance with the review literature. The patient gave history of tobacco chewing as well as habit of holding the tobacco quid in the buccal vestibule since 18 years with chronic alcohol consumption. These findings are one of the most common risk factors associated with OSCC mentioned in the literature.

OSCC of the gingiva from radiographical aspect often resembles periodontal disease which bestows a floating tooth manifestation, which was not apparent in the present case series. Initial radiographic examination in doubtful cases is usually the intraoral peri-apical radiograph. The Radiographic evaluation from intraoral peri-apical radiograph may show extensive bone loss.Early invasion is suggested combined with orthopantomogram and bone scintigraphy for diagnosis of Squamos cell carcinoma of gingiva. Magnetic resonance imaging (MRI) is more susceptible for bony invasion than computerized tomography (CT) & cone beam computed tomography scan (CBCT). CT & CBCT scanning provides extra details on the extent of alveolar bone involvement, malignant infiltration and cervical nodal disease. Ultrasound guided fine needle aspiration cytology (FNAC) has the greatest precision in the clinically adverse neck diagnosis of cervical nodal metastasis relative to ultra sonography, CT scan and MRI.(16-19)

Picking the best therapy for SCC of the oral cavity is relied on patient factors and tumor factors. Patient

factors consist of the nutritional status, related diseases, and oral habits, while tumor factors comprise of its size, site, histology, and biologic behavior. Classically buccal carcinoma has been treated surgically & the therapeutic strategies varied from maxilla and mandible resection, radical dissection of the neck relying on the degree of the invasion, and extension through lymphatic nodes. While postoperative radiation therapy is reserved for patients with high-risk histopathologic findings, such as perineural invasion, lymphovascular invasion, bone invasion, extracapsular spread, or close margins. (5, 20, 24)

The treatment of primary gingival SCC usually consists of excision with 1 cm of clear margins, with or without neck dissection. Inclusion of the neck dissection procedure depends upon the presence of cervical lymph node metastases. Smaller lesions are typically treated with wide excision alone, and radiation therapy serves as a backup in the event of recurrence. Survival rate of patients with gingival carcinomas depends upon the clinical stage at the time of diagnosis. If the neoplasm is small and localized, the 5 year survival rate is around 60–70%; however, but if cervical nodal metastasis occurs the survival rate drops to about 25% signifying that early diagnosis is crucial. (21-22)

Combination of surgery and postoperative radiotherapy is the suggested treatment for advanced squamous cell carcinoma of the head and neck. In few review literature revealed that postoperative radiotherapy was observed to be less effective in cancers of the oral cavity than in those in the laryngopharynx and oropharynx, but comparative study by Sanjay Dixit, MD, Rakesh K. Vyas

et.al showed that post operative radiotherapy in Squamous Cell Carcinoma of the buccal mucosa, was effective in decreasing locoregional failure in patients

with close surgical margins, tumor thicker than 10 mm, high-grade tumors, positive node, and bone invasion. The effect of interval between surgery and postoperative radiotherapy on local failure was margin-dependent. (23)

In our case series the wide resection with neck dissection was mainstay of cancer treatment to avoid recurrence of the tumor. In Case 1 treated using unilateral maxillectomy with modified radical neck dissection without postoperative radiotherapy. In Case 2 treated using hemi mandibulectomy with modified radical neck dissection. Radiotherapy or chemotherapy was not considered in postoperative phase. In Case 3, wedge resection followed by supra-omohyoid neck dissection.

Conclusion

Squamous cell carcinoma is not only most prevalent malignancy of oral cavity but also is one of the most common sites of head and neck squamous cell carcinoma. The Squamous cell carcinoma of oral cavity has a varied etiology as well as myriad clinical appearances. The early lesions of SCC often mimic benign inflammatory lesions. General dental practitioner & maxillofacial surgeons are usually encountering these lesions in their initial stages. A missed diagnosis in their initial stages often happens due to mimicking nature of SCC, which directly affects the prognosis of the disease. Delayed diagnosis severely affects course of the disease & likelihood of living. Hence it become necessary for the clinician to consider the possibility of malignancy in common benign inflammatory lesions lesion which does not responds to conventional treatment methods. Surgical excision & neck dissection is the mainstay of treatment of SCC of oral cavity.

Reference

1. Chen GS, Chen CH. A statistical analysis of oral squamous cell carcinoma. *Kaohsiung J Med Sci* 1995; 1:582-8.
2. Marocchio LS ,Lima J et.al. oral squamous cell carcinoma analysis of 1,564 showing advances in early detection. *J Oral Sci* 2010;52,267-273.
3. Seoane J, Varela-Centelles PI, Walsh TF, Lopez-Cedrun JL,Vazquez I. Gingival squamous cell carcinoma: Diagnostic delay or rapid invasion? *J Periodontol* 2006;77:1229-33.
4. Bloom ND, Spiro RH: Carcinoma of the cheek mucosa:A retrospective analysis. *Am J Surg* 140:556-559,1980.
5. Strome SE, To W, Strawderman M, et al: Squamous cell carcinoma of the buccal mucosa. *Otolaryngol Head Neck Surg* 120:375-379, 1999.
6. Rakhewar PS, Kanjalkar V, Syed R. Gingival Squamous Cell Carcinoma: A Case Report. *IOSR Journal of Dental and Medical Sciences (JDMS)* 2012;1(6):21-3.
7. Romita Dilip Gaikwad ,Mukta Bhagwandas Motwani ,Kalpana Anil Bothale ,Sanyukta Rajeev Golhar , Apurva Subodh Mohite ,Oral Squamous Cell Carcinoma: An Unusual Presentation .*Int J Dent Health Sci* 2016; 3(4): 840-844.
8. Bodner L,Manor E, Friger MD, van der Waal I. Oral squamous cell carcinoma in patients twenty years of age or younger--review and analysis of 186 reported cases. *Oral Oncol* 2014;50(2):84-9.
9. Soo KC, Spire RH, King W, Harvey W, Strong E. Squamous carcinoma of the gums. *Am J Surg* 1988;156:281-5.
10. Meleti M, Corcione L, Sesenna E, Vescovi P. Unusual presentation of primary squamous cell carcinoma involving the interdental papilla in a young woman. *Br J Oral Maxillofac Surg* 2007;45(5):420-2.
11. Barasch A, Morse DE, Krutchkoff DJ, Eisenberg E. Smoking, gender, and age as risk factors for site specific intraoral squamous cell carcinoma. A case series analysis. *Cancer* 1994;73:509–13.
12. Magalhaes MAO, Somers GR, Sikorski P, Forte V, Abouzgia M, Barrett E,Bradley G, Unusual presentation of squamous cell carcinoma of the maxilla in an 8-year-old child, *Oral Surgery, Oral Medicine, Oral Pathology and Oral Radiology* (2016), doi: 10.1016/j.oooo.2016.06.017.
13. Sidell et al.: Pediatric Squamous Cell Carcinoma,*Laryngoscope* 119: August 2009,1538-1541.
14. Binahmed A, Makepeace C, Campisi P, et al. Primary squamous cell carcinoma of the maxillary alveolus in a 10-year-old girl. *JCDA* 2007;73:715–718
15. Elizabeth Sieczka, Rajiv Datta, Anand Singh, Thom Loree, MD, Nestor Rigual, James Orner, and Wesley Hicks.Cancer of the Buccal Mucosa: Are Margins and T-Stage Accurate Predictors of Local Control?.*Am J Otolaryngol* 2001;22:395-399.
16. Sanjeev misra, arun chaturvedi, nc misra. Management Of Gingivobuccal Complex Cancer.*ann r coll surg engl* 2008; 90: 546–553.
17. KH Lee,MJ Veness,T Pearl-Larson,GJ Morgan.Role of combined modality treatment of buccal mucosa squamous cell carcinoma.*Australian Dental Journal* 2005;50:2,108-114.
18. Roshni Ramesh, Arun Sadasivan. Oral squamous cell carcinoma masquerading as gingival overgrowth.*Eur J Dent* 2017;11:390-4.

19. Langlais RP, Langland OE, Nortje CJ. Diagnostic imaging of the jaws. 1st ed. Williams and Wilkins; 1995.p.33.
20. Fang FM, Leung SW, Huang CC, et al. Combined-modality therapy for squamous carcinoma of the buccal mucosa: treatment results and prognostic factors. *Head Neck* 1997;19:506-12.
21. Heller AN. Squamous cell carcinoma of the gingival. A review. *NY State Dent J* 1994;60:31-3.
22. Bharanidharan R, Dineshkumar T, Raghavendhar K, Kumar AR. Squamous cell carcinoma of the gingiva: A diagnostic enigma. *J Oral Maxillofac Pathol* 2015;19:267.
23. Peters LJ, Goepfert H, Ank KK, et al. Evaluation of the dose for postoperative radiation therapy of head and neck cancer: first report of a prospective randomized trial. *Int J Radiat Oncol Biol Phys* 1993; 26:3-11.
24. Bajaj P, Garg D, Multani RK, Gautam S. Squamous cell carcinoma of gingiva: An enigmatic lesion. *SRM J Res Dent Sci* 2016; 7:194-7.
25. Devki SM, Hange VB. A Rare Gingivobuccal Complex Cancer in a Pediatric patient: A Case Report. *Avicenna J Dent Res.* 2019;11(3):104-107. doi: 10.34172/ajdr.2019.20
26. Hange VB, Devki SM et.al. A Rare Squamous Cell Carcinoma Of Mandible, Mimicking Chronic Osteomyelitis: Case Report. *International Journal of Medical Science and Diagnosis Research* .Volume 4, Issue 4; April: 2020; Page No. 22-25.