

**Role of Magnetic Resonance Imaging (MRI) in the Detection of Cervical Invasion in Patients with Endometrial Cancer: A Hospital Based Prospective Study**

<sup>1</sup>Saritha V, Assistant Professor, Department of Radiodiagnosis, Government Medical College, Palakkad, Kerala.

<sup>2</sup>Jayasree L, Professor, Department of Radiodiagnosis, Government Medical College, Trivandrum, Kerala.

**Corresponding Author:** Saritha V, Assistant Professor, Department of Radiodiagnosis, Government Medical College, Palakkad, Kerala.

**Citation this Article:** Saritha V, Jayasree L, “Role of Magnetic Resonance Imaging (MRI) in the Detection of Cervical Invasion in Patients with Endometrial Cancer: A Hospital Based Prospective Study ”, IJMSIR- December - 2020, Vol – 5, Issue - 6, P. No. 66 – 70.

**Type of Publication:** Original Research Article

**Conflicts of Interest:** Nil

**Abstract**

**Background:** Magnetic Resonance Imaging (MRI) plays major role in the diagnosis of various diseases. The present study is aimed to evaluate the role of MRI in the detection of cervical invasion in patients with endometrial carcinoma.

**Materials and Methods:** The study included total of 55 patients based on inclusion and exclusion criteria. All patients were explained the study procedure and informed consent was obtained. They were subjected to MRI for the detection of cervical invasion. The demographic and clinical data was recorded and analyzed. Microsoft excel and SPSS (16.0) version was used for analysis.

**Results:** This study included 55 patients. Due to various reasons 4 patients lost the follow up and finally 51 patient’s images were analyzed. In the study maximum patients had age between 61-70 years. 12 patients showed the cervical invasion in MRI scanning which is similar to histopathology reports. The study results showed 90.90 % sensitivity and 95.0% specificity between the MRI and histopathology.

**Conclusion:** The study results showed MRI is one of the best tools to detect the cervical invasion in endometrial carcinoma.

**Keywords:** MRI, endometrium, cervical invasion, bleeding, pain, histopathology

**Introduction**

The signal intensity of endometrial tumors is usually hyperintense to the myometrium and slightly hypointense to the normal endometrium at T2-weighted images<sup>1</sup>. Although MRI imaging cannot differentiate benign from malignant intracavitary endometrial neoplasm, benign endometrial polyps can be suspected when a central hypo intense fibrous core is identified at T2-weighted images in the enlarged uterine cavity<sup>2,3</sup>. However, hypo intensity within the uterine cavity is not a specific finding and can be related to fresh blood. The extension of the lesion into the cervical canal/cervical stroma can be well made out in MRI and this finding points to malignancy.

Hardesty et.al., reported sensitivities of 100% and 83% for MRI and surgical staging, respectively. There were significant number of unnecessary nodal dissections

when the surgical approach was based on surgical staging. No cases of understaging by MRI were found. MRI helped to avoid unnecessary nodal dissection and to correctly perform dissection in cases with deep infiltration. In their series, if the surgical decision was based only on MRI findings, the additional cost would have been only 1%. They conclude that MRI may replace gross surgical staging. Surgical staging also prolongs the duration of surgery<sup>6</sup>.

As proposed by Cunha et.al., MRI and surgery may be used alternatively in staging EC, with the decision depending also on the local surgical skills and the availability of MRI. Moreover, an accurate preoperative MRI investigation may lead to a less invasive surgical approach (laparoscopy, mini-laparoscopy), resulting in reduced perioperative morbidity, in particular in elderly patients and patients with cardiovascular and metabolic comorbidities. For prediction of deep myometrial and cervical invasion MRI has the greatest discriminatory power, but costs more than ultrasonography and computed tomography<sup>7</sup>.

As suggested by Heller et.al., MRI has little clinical consequence in comparison to ultrasonography when considering grade 1 tumors, but may be cost-effective for grade 3 tumors considering the high costs of surgery and disease management<sup>8</sup>. From the knowledge of above studies the present study aimed to evaluate the role of MRI in detection of cervical invasion patients with endometrial cancer.

## Materials and Methods

**Study settings and Time:** This study was done in the Department of Radiodiagnosis. Government Medical College, Trivandrum, Kerala. It is a prospective study and it was ethically cleared by Institutional Human Ethics Committee (IHEC). The study period is

## Inclusion criteria

- HPR proven endometrial cancer
- Patients willing for surgery
- Above 45 years

## Exclusion criteria

- Cannot perform surgery
- High risk
- On radiation therapy
- On chemotherapy
- Past surgical history

## Procedure

This study included 55 patients based on the inclusion and exclusion criteria. Only 51 patients completed the study. All the patients explained the study procedure in their own language. They were asked to sign in the informed consent form. Demographic and clinical data was collected and recorded. The patients were subjected to MRI and reports were analyzed.

## Statistical analysis

Statistical Package for Social Sciences (SPSS 16.0) version used for analysis. The data was expressed in number, percentage, mean and standard deviation. Micro soft excel sheet 2009 used for making the graphs.

## Results

Total 51 patients were analyzed in the study. Maximum number patients had age between 61-70 yrs (n=35) followed by 51-60 yrs (n=9). 2 patients had age less than 50 yrs and 5 had more than 70 yrs (Graph-1). In the MRI 12 showed cervical invasion and 39 showed no invasion which is statistically significant (Table-1). 11 showed invasion and 40 did not show invasions in histopathology study (Table-2). The comparison between the MRI and histopathology reports showed sensitivity (90.9%), specificity (95.0%), positive

predictive value 83.33%, negative predictive value 97.43 and accuracy 94.11 (Graph-2).

### Discussion

Endometrial carcinoma is the most common in women with age between 40-60y. MRI is not commonly used for the diagnosis of endometrial cancers but routinely used for staging. This present study included the 51 patients with endometrial cancer to screen the invasion. Most of the patients had age between the 61-70 years. Infiltration of the uterine cervix is detected as a high-signal-intensity mass within the endocervical canal and/or disruption of the normal low-signal-intensity cervical stroma. Presence of enlarged pelvic and/or lumboaortic lymph nodes were also analysed separately -cutoff value, 10 mm along the minimal transverse diameter

Most of the patients patients presented with postmenopausal bleeding.

Analysis of cervical invasion out of the total 11 patients with cervical invasion in HPR, 10 patients had cervical invasion in MRI also. One patient was false negative and two patients were false positive. On retrospective evaluation the false positive results were due to preexisting cervicitis. In cervicitis there was abnormal enhancement of the cervical tissue. In our study MRI is 90.9% sensitive in evaluating the cervical invasion, the specificity is 95.0%, PPV-83.33%, NPV-97.43%, Accuracy-94.11%

In the study by Fathima et.al., MRI also accurately staged presence of cervical invasion in 8 (16%) and absence of cervical invasion in 40 (80%) out of 50 patients. One patient was underdiagnosed with cervical invasion. MR imaging assessment of cervical infiltration by endometrial carcinoma resulted in eight (22%) of 37 patients with true-positive, 26 (70%) patients with true-negative, two (5%) patients with

false-negative, and one (3%) patient with false-positive results. Overall MR imaging sensitivity, specificity, diagnostic accuracy, and positive and negative predictive values in the assessment of cervical infiltration were 80%, 96%, 92%, 89%, and 93%, respectively.

In the study by Franco Zandrino et.al., 96 Contrast-enhanced sequences reached a sensitivity of 100%, specificity of 94%, PPV of 75%, NPV of 100%, and accuracy of 95% in evaluating cervical invasion. Their study results proved that MRI can be used as a diagnostic tool to screen the endometrial invasion in patients with endometrial cancer.

### Conclusion

MRI can use as a diagnostic tool in the detection of endometrial invasion in endometrial cancer. It showed significant sensitivity and specificity with histopathology. MRI scan can use alternative tool to detect the endometrial invasion in cancer patients

### References

1. Takeuchi M, Matsuzaki K, Uehara H, Yoshida S, Nishitani H, Shimazu H. Pathologies of the uterine endometrial cavity: usual and unusual manifestations and pitfalls on magnetic resonance imaging. *Eur Radiol* 2005;15:2244–55.
2. Popovich MJ, Hricak H, Sugimura K, Stern JL. The role of MR imaging in determining surgical eligibility for pelvic exenteration. *AJR Am J Roentgenol* 1993;160:525–31.
3. Grasel RP, Outwater EK, Siegelman ES, Capuzzi D, Parker L, Hussain SM. Endometrial polyps: MR imaging features and distinction from endometrial carcinoma. *Radiology* 2000;214:47–52.
4. Nasi F, Fiocchi F, Pecchi A, Rivasi F, Torricelli P. MRI evaluation of myometrial invasion by endometrial carcinoma. Comparison between fast-

spin-echo T2w and coronal- FMPSPGR Gadolinium-Dota-enhanced sequences. RadiolMed 2005;110:199-210.

5. Yamashita Y, Harada M, Sawada T, Takahashi M, Miyazaki K, Okamura H. Normal uterus and FIGO stage I endometrial carcinoma: dynamic gadolinium-enhanced MR imaging. Radiology 1993;186:495-501.
6. Hardesty LA, Sumkin JH, Nath ME, Edwards RP, Price FV, Chang TS, Johns CM, Kelley JL. Use of preoperative MRI imaging in the management of endometrial carcinoma: cost analysis. Radiology 2000; 215: 45-9.
7. Cunha TM, Félix A, Cabral I. Preoperative assessment of deep myometrial and cervical invasion in endometrial carcinoma: comparison of magnetic resonance imaging and gross visual inspection. Int J Gynecology Cancer 2001;11:130-6.
8. Heller D, Hricak H. Cost-effectiveness of new technologies for staging endometrial cancer. Eur Radiology 2000;10(3):381-5.
9. Evis S, Suzanne W, Emma S, David L. MRI of malignant neoplasms of the uterine corpus and cervix. AJR 2007;188(6): 1577-87.
10. Fatima M, Waseem AM. Staging of endometrial carcinoma by magnetic resonance imaging: Correlation with surgery and histopathology. JPMA 2009;59(9):622-5.
11. Franco Z, Ernesto LP, Francesco M. Magnetic resonance imaging in local staging of endometrial carcinoma: Diagnostic performance, pitfalls and literature review. Tumori Journal 2018;29:1567-72.

Graph 1: Distribution of patients based on the age

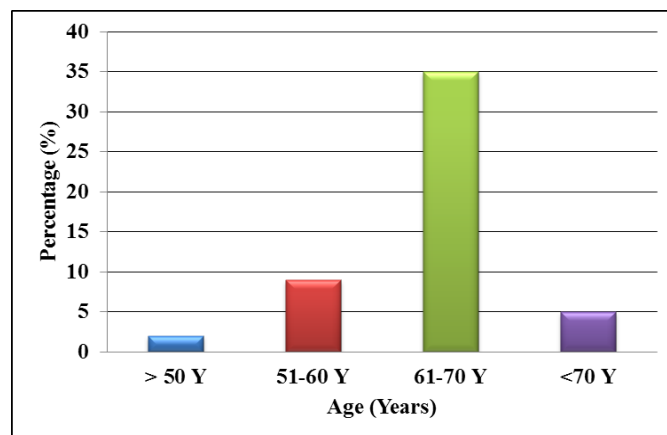


Table 1: Distribution of patients based on the cervical invasion in MRI

Cervical invasion MRI	Number (n=51)	Percentage (%)
No	39	76.50
Yes	12	23.50
Total	51	100.00

Table 2: Distribution of patients based on the cervical invasion in histopathology report

Cervical invasion histopathology report	Number (n=51)	Percentage (%)
No	40	78.40
Yes	11	21.60
Total	51	100.00

Graph 2: Sensitivity, specificity, positive predictive value, negative predictive value and accuracy of MRI and histopathology report

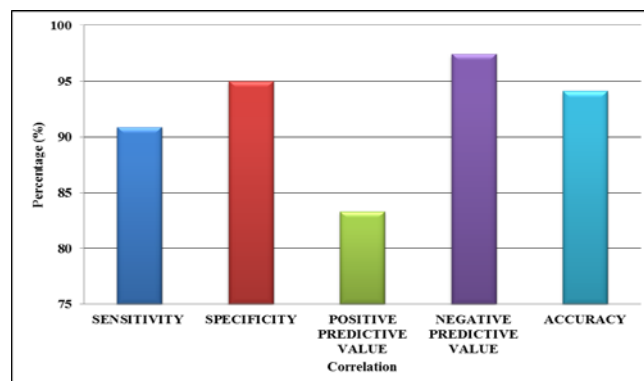

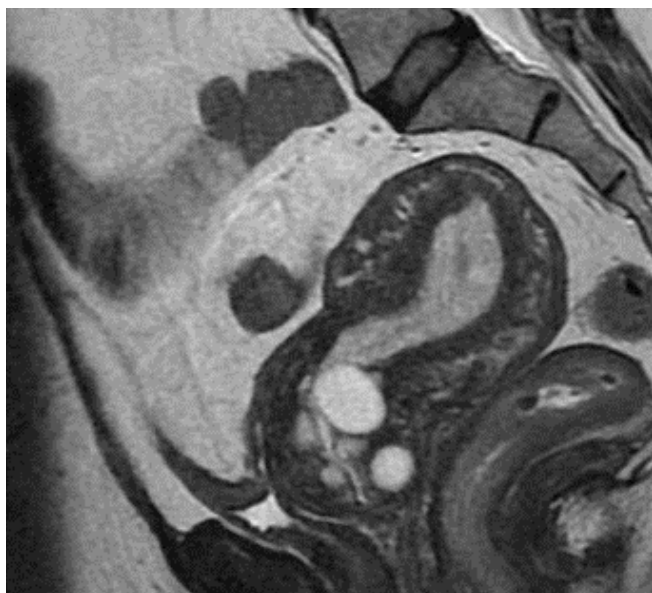


Figure 1: Stage 2 disease with cervical invasion. Multiple nabothian follicles noted in the cervical canal

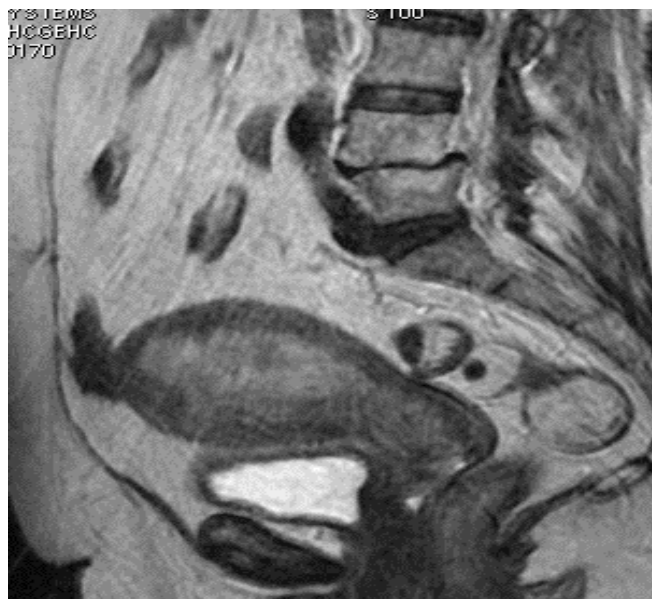

Figure 3: T2W sagittal image showing myometrial invasion and cervical invasion stage 2 d/s

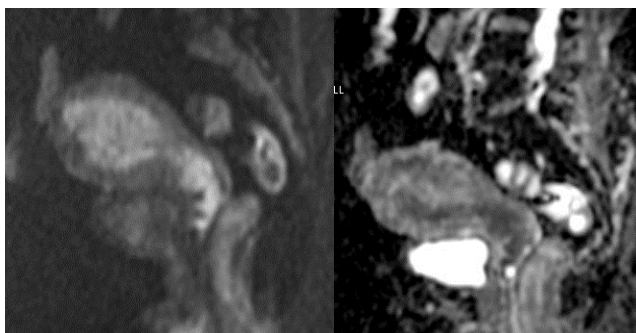

Figure 2: Diffusion weighted imaging and ADC mapping shows restricted diffusion extending to the cervical canal with widening of cervical canal- features consistent with stage 2 disease