

Tooth Supported Overdenture Using Castable Precision Attachments with Modified Impression Technique: A Case Series

¹Dr. Mokashi Kanchan, MDS Student, Department of Prosthodontics and Implantology, C.S.M.S.S Dental College and Hospital, Chhatrapati Sambhajnagar (Aurangabad), Maharashtra, India.

¹Dr. Nelanuthala Keerthi Meghana, MDS Student, Department of Prosthodontics and Implantology, C.S.M.S.S Dental College and Hospital, Chhatrapati Sambhajnagar (Aurangabad), Maharashtra, India.

²Dr. Adhapure Prasad, Professor, Department of Prosthodontics and Implantology, C.S.M.S.S Dental College and Hospital, Chhatrapati Sambhajnagar (Aurangabad), Maharashtra, India.

³Dr. Yeshwante Babita, Professor and HOD, Department of Prosthodontics and Implantology, C.S.M.S.S Dental College and Hospital, Chhatrapati Sambhajnagar (Aurangabad), Maharashtra, India.

Corresponding Author: Dr. Nelanuthala Keerthi Meghana, MDS Student, Department of Prosthodontics and Implantology, C.S.M.S.S Dental College and Hospital, Chhatrapati Sambhajnagar (Aurangabad), Maharashtra, India.

Citation this Article: Dr. Mokashi Kanchan, Dr. Nelanuthala Keerthi Meghana, Dr. Adhapure Prasad, Dr. Yeshwante Babita, “Tooth Supported Overdenture Using Castable Precision Attachments with Modified Impression Technique: A Case Series”, IJMSIR - June – 2025, Vol – 10, Issue - 3, P. No. 67 – 76.

Type of Publication: Case Series

Conflicts of Interest: Nil

Abstract

Preventive prosthodontics emphasizes preserving natural teeth to enhance prosthetic stability and longevity. Tooth-supported overdentures serve as a crucial treatment modality, improving retention, reducing alveolar bone resorption, and providing psychological benefits to patients. This paper presents a series of case reports demonstrating the successful rehabilitation of a partially edentulous mandibular arch using a tooth-supported overdenture with precision attachments and copings. A detailed clinical approach, including case selection, treatment planning, and prosthetic execution, is discussed to highlight the advantages of this cost-effective alternative to conventional complete dentures and implant-supported prostheses.

Keywords: Tooth supported overdenture, precision attachments, Rhien 83, Castable ball attachments

Introduction

Preventive prosthodontics involves procedure that can delay or eliminate future prosthodontic problems and Tooth-supported overdentures constitute an important concept in preventive prosthodontics. DeVan’s golden statement: “Perpetual preservation of what remains is more important than the meticulous replacement of what is missing” still holds true and Tooth-supported overdenture has been recommended by preventive prosthodontics for preserving the remaining natural teeth as well as providing stability and additional retention to the prostheses, especially in mandible.^{1,2,3}

In the quest of preserving the existing dentition, the most often overshadowed treatment modality is the Tooth

supported overdenture which needs the limelight. The idea of conventional tooth-supported overdentures is a modest and cost-effective treatment when compared to implant overdentures and is definitely a better option to the conventional complete denture in terms of retention and pace of future bone resorption that can occur in completely edentulous patients.^{4,5}

According to Glossary of Prosthodontic Terms (GPT 10), an overdenture is a complete or removable denture that rests on one or more remaining natural teeth, roots, or dental implants; a dental prosthesis that is partially supported by natural teeth, tooth roots, and/or dental implants. It is also known as overlay prosthesis, overlay denture, and superimposed prosthesis.⁶

In tooth-supported overdentures, the teeth are maintained as part of the residual ridge as it provides psychological benefit to the patients, one of its most important advantages.^{7, 8} The presence of periodontal ligament in tooth-supported overdentures plays an important role in shock absorption, the maintenance of proprioception, and functional stimulus for bone preservation, which improves the retention, stability, support, and masticatory efficiency of the patient. Retaining natural teeth improves sensory feedback, making it easier for the patient to control bite force and chewing efficiency.^{9, 10, 11}

Indications

Tooth-supported overdentures are recommended in the following cases:⁸

- Patients with presence of residual healthy teeth bilaterally.
- Patients at risk of losing their remaining natural dentition.
- Situations where achieving adequate retention is challenging, such as:
 - Xerostomia (reduced salivary flow).
 - Severely resorbed residual alveolar ridges.

- Partial loss of maxillary and mandibular bone
- Patients with congenital conditions like cleft palate.
- Patients with developmental anomalies like cleidocranial dysplasia or ectodermal dysplasia, where conventional prosthetic solutions are challenging.
- Cases with compromised retention, including:
 - High-arched palates and steep ridge slopes.
 - Inadequate lingual seal due to tongue position.
 - Knife-edge mandibular ridges.
- Situations where vertical overlap of anteriors is needed for improved aesthetics.
- Unilateral overdentures can be considered when there is significant bone loss on one side of the residual arch.

Contraindications

- Tooth-supported overdentures may not be suitable for:⁸
- Uncooperative or less motivated patients who prefer complete removal of their remaining teeth.
- Patients with periodontally compromised or extensively carious remaining natural teeth.
- Patients with poor oral hygiene.
- Individuals who do not prefer removable prostheses.
- Mentally or physically challenged patients who cannot maintain adequate oral hygiene.

This article presents a series of case reports on the successful rehabilitation of a partially edentulous mandibular arch using a tooth supported overdenture with Precision attachments and copings.

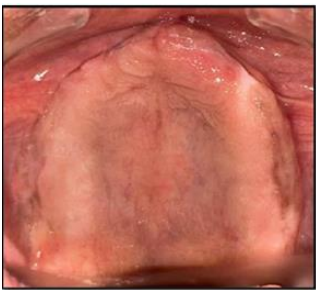Case Report - 1

A 75-year-old male patient reported to the Postgraduate Department of Prosthodontics and Crown & Bridge & Implantology, CSMSS Dental College and Hospital, Chh. Sambhajinagar with a chief complaint of difficulty in chewing food due to missing teeth in his upper and lower

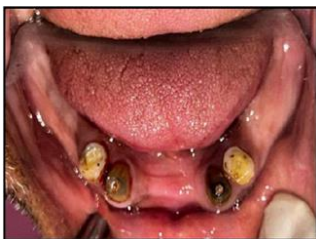jaw since 8 months. Patient had a fixed dental prosthesis with respect to mandibular anteriors (from 33 to 43) with abutments 33 and 43 which were root canal treated; 6 years ago. The prosthesis was removed 1 month ago by a dentist.

The medical history of the patient was not significant. On extra-oral examination, the facial form was found to be ovoid with a Class I facial profile and lip length was found to be average.

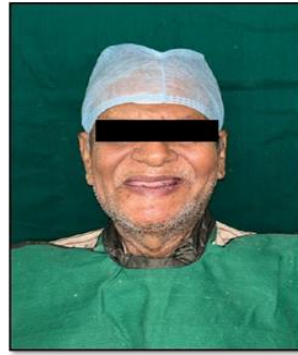Intraoral examination revealed completely edentulous maxillary arch and partially edentulous mandibular arch with teeth remaining- 33, 34, 43 and 44. The remaining teeth were non-carious and had good periodontal support. The canines i.e., 33 and 43 were treated with root canal. The maxilla-mandibular relation was Class I with adequate inter-arch space present in the premolar region. Based on the clinical and radiographic findings, it was decided to fabricate a conventional maxillary complete denture and a mandibular ball attachment retained with 33 and 43 and coping attachment with 34 and 44, tooth supported overdenture. The patient was informed about the proposed treatment plan and a consent was obtained.



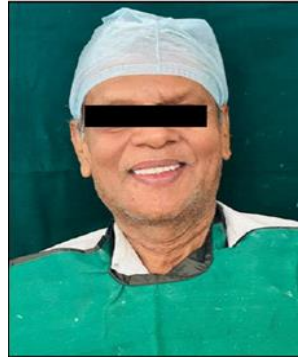Pre-operative intra-oral view (Maxillary arch)



Pre-operative intra-oral view (Mandibular arch)



Pre-operative extra-oral view



Post-operative extra-oral view

Case Report - 2

A 62-year-old female patient reported to the Postgraduate Department of Prosthodontics and Crown & Bridge, CSMSS Dental College and Hospital, Chh. Sambhajinagar with a chief complaint of difficulty in chewing food and impaired aesthetics due to multiple missing teeth in her upper and lower jaw. Patient was using an acrylic removable partial denture with the mandibular teeth 36, 37, 46, 47, for past 2 years. She was discontented with the retention and stability of this prosthesis.

The medical history of the patient revealed that she is diabetic and has hypothyroidism and is on the medications for the same since past 8 years.

On extra-oral examination, the facial form was found to be ovoid, symmetrical with a Class I facial profile and average lip length.

Intraoral examination showed:

- Missing teeth: 17, 25, 26, 27, 36, 37, 41, 46, 47

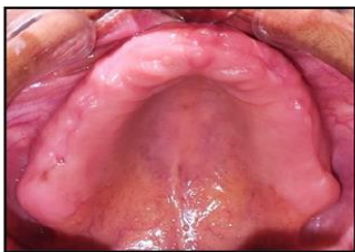- Root pieces: 11,12, 13, 14, 21, 22, 23, 24, 31, 32, 35, 42, 45
- Grade 3 mobility: 15, 16
- Proximal Caries: 33, 34, 43, 44

The entire treatment was planned and divided into three stages:

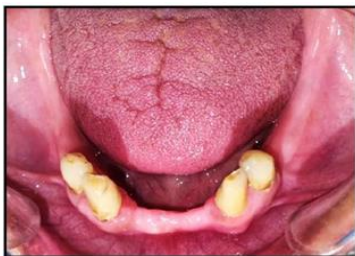1. Surgical phase: Extractions were performed for 11,12, 13, 14, 15, 16, 21, 22, 23, 24, 31, 32, 35, 42, 45
2. Endodontic phase: Root canal treatment was performed for 33, 34, 43, 44
3. Prosthetic phase

After the pre-prosthetic phase, a completely edentulous maxillary arch was seen. The remaining teeth 33, 43, 43, 44 in the mandibular arch had good periodontal support. The maxilla-mandibular relation was Class I with adequate inter-arch space present.

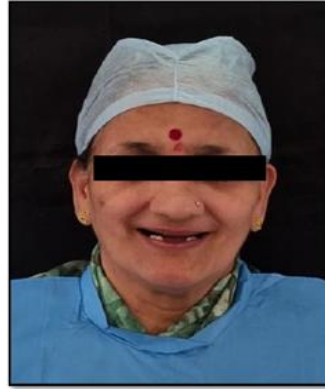Based on the clinical and radiographic findings, it was decided to fabricate a conventional maxillary complete denture and a mandibular ball attachment retained with 33 and 43 and coping attachment with 34 and 44, tooth supported overdenture. The patient was informed about the proposed treatment plan and a consent was obtained.



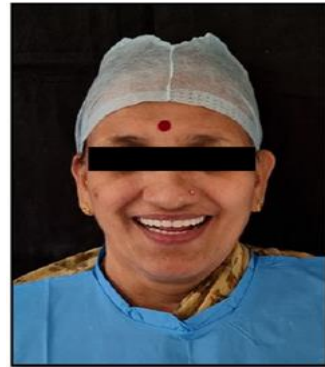Pre-operative intra-oral view (Maxillary arch)



Pre-operative intra-oral view (Mandibular arch)



Pre-operative extra-oral view



Post-operative extra-oral view

Procedure for Prosthetic Phase

Preliminary impressions were made with alginate and diagnostic casts were fabricated for further evaluation. Considering the inter-arch space availability, it was decided to give ball attachments for 33 and 43 whereas metal copings were planned for 34 and 44. In order to obtain a favourable crown root ratio for metallic copings and ball attachments, it was decided to proceed with intentional root canal treatment of 34 and 44 as well.

Tooth preparations were carried out in mandibular teeth after the endodontic treatment of the same.

The teeth were prepared in a dome-shaped contour with approximately 1-1.5mm projecting above the gingiva.

Post space impression was made using light body consistency addition silicone material. A plastic pinjet was placed in the post space to measure the length and for the stabilization of the light body material. Plastic

pattern of ball and socket attachments (Rhein-83 ball attachments) were attached.

Impression of the mandibular arch was made with addition silicone after adequate gingival retraction. The mandibular casts procured were sent to the laboratory for the fabrication of attachments.

After an adequate fit of metal copings and ball attachments were ensured, they were cemented to their respective abutments using GIC luting cement.

Customized special trays were fabricated with self-cure acrylic resin for maxillary and mandibular arch. Border moulding was done using low fusing impression compound and final impressions were made with light body addition silicone impression paste to obtain master casts. Here, the mandibular arch impression was made by placing the female attachment over the ball attachment.

Temporary record bases and wax rims were fabricated followed by jaw relations and face bow transfer to the semi-adjustable articulator. Teeth arrangement was done to achieve bilateral balanced occlusion.

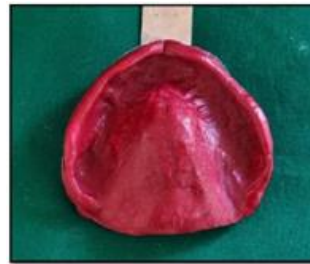The centric relation, vertical relation, phonetics and aesthetics were evaluated in the patient's mouth. On satisfaction of the patient, the dentures were fabricated using heat cure acrylic resins. Maxillary complete denture was inserted in a conventional manner.

Since the impression was taken by placing the female attachments; there was no need to create window to accommodate the attachments. The female attachments were directly placed on the male components and cold-cure acrylic resin was flowed on the intaglio surface of the denture where the female attachment is supposed to be picked.

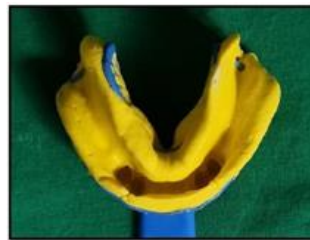The denture was then placed and allowed to set.

Once set, the female components were picked along with the mandibular denture from the oral cavity. The excess flash of resin was trimmed and the dentures were finished

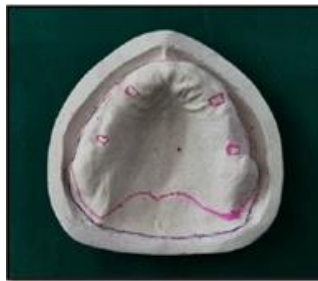and polished followed by insertion. The post-insertion instructions were given to the patient and follow up recalls were done after 24 hours, one week and one-month intervals.



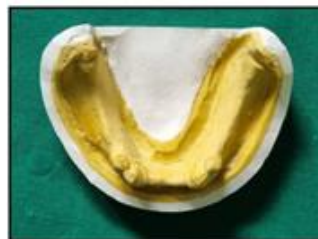Primary impression of maxillary arch



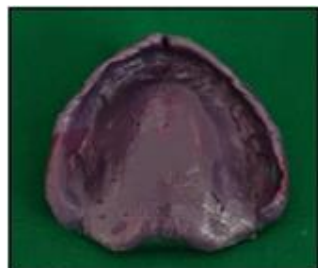
Primary impression of mandibular arch



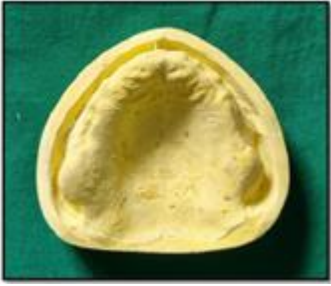Primary cast of maxillary arch



Primary cast of mandibular arch



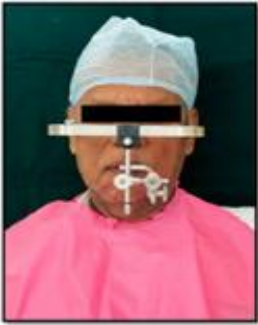Final impression of maxillary arch



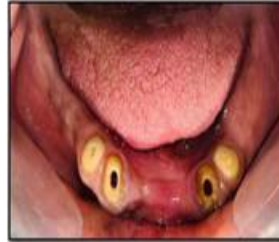Master cast of maxillary arch



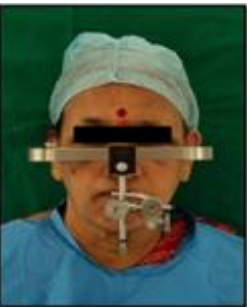Mandibular arch mounting



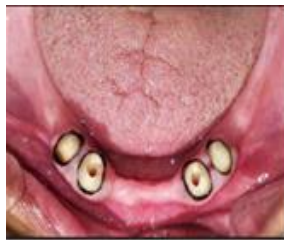Facebow record



Post space preparation for cast post with #33 & #43



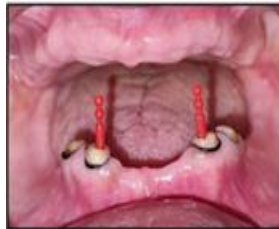Facebow record



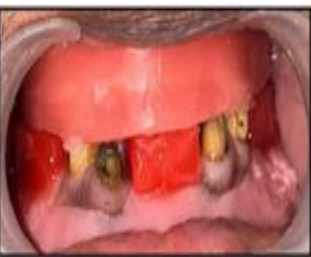Gingival retraction



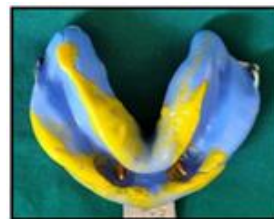Facebow transfer on a semi-adjustable articulator



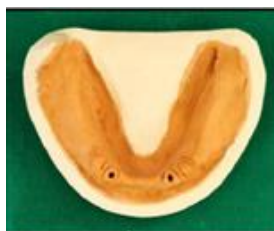Placement of pinjet for stability of post space impression




Jaw relation



Mandibular impression with post-space



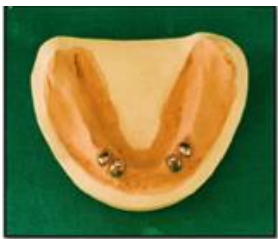Final mandibular cast with post-space



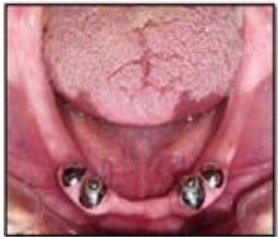Rhein-83 attachments



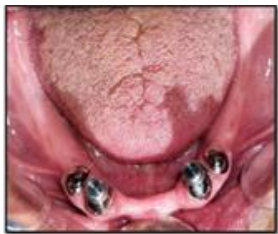Casted attachments



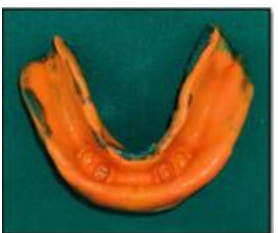Casted attachments on cast



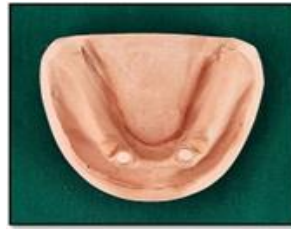Casted attachments cemented with the luting GIC



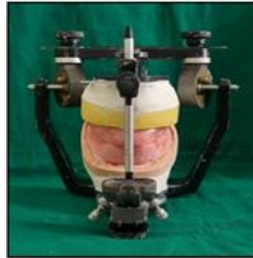Female attachment placed over male attachments



Impression recorded with A-silicone



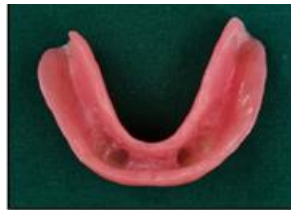Final master cast



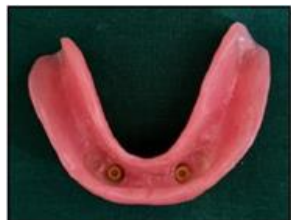Final mounting with centric record



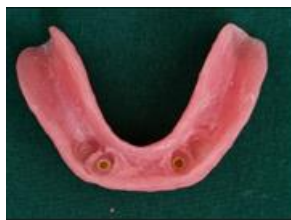Teeth arrangement in MIP



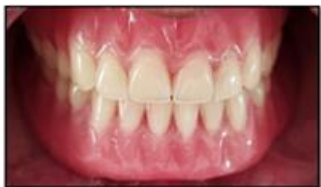Final acrylization with space for female attachments



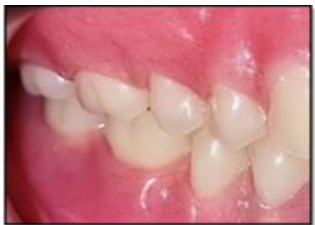Trial of female attachments



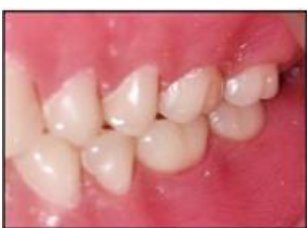Pick-up of female attachments with cold cure acrylic material



Final prosthesis- frontal view



Occlusion- right lateral view



Occlusion- left lateral view

Discussion

The success of an overdenture prosthesis is highly dependent on the careful selection of a suitable patient and the implementation of a meticulously planned treatment approach. Both the functional and aesthetic outcomes must align with the expectations of the patient and the clinician to ensure long-term satisfaction. Overdentures offer a viable solution for patients with partial or complete edentulism by utilizing existing tooth roots or implants to enhance support, stability, and retention.

Several clinical techniques can be employed for the rehabilitation of lost dentition using overdentures. These techniques vary based on the condition of the remaining dentition and the specific needs of the patient. The most commonly used approaches include:

1. **Tooth Modification and Reduction** – Involves reshaping the remaining teeth to improve denture adaptation and retention.

2. **Tooth Reduction with a Cast Coping** – A metal coping is placed over the reduced tooth structure to provide additional strength and stability.
3. **Endodontic Therapy Followed by Cast Coping** – Root canal treatment is performed on the remaining teeth, followed by the placement of cast copings to preserve tooth structure and improve prosthetic support.
4. **Endodontic Therapy Combined with an Attachment System** – Root canal-treated teeth serve as abutments for an attachment system that enhances the retention and stability of the overdenture.

Among these approaches, the incorporation of an attachment system is particularly beneficial for patients with significant alveolar bone resorption, as it offers superior prosthetic retention compared to conventional techniques. In such cases, an attachment system helps compensate for the loss of natural tissue support and improves the overall function of the prosthesis.

Selection of The Rhien 83 Ball-And-Socket Attachment System

In this particular case, the Rhien 83 ball-and-socket attachment system was chosen to optimize overdenture retention and stability. This system consists of two primary components:

- **Male Ball Component** – This component is typically in the form of a post that extends into the root canal of an endodontically treated tooth, serving as the primary retentive structure.
- **Female Component (Retention Ring)** – This is embedded within the tissue side of the denture and engages with the male ball attachment to provide secure fixation.

Several key factors influenced the decision to utilize the Rhien 83 attachment system:

1. **Simplicity of Design and Application:** The system is straightforward to incorporate into the prosthesis, making it an efficient solution for both the clinician and the patient.
2. **Capacity to Withstand Occlusal Forces:** The ball-and-socket mechanism provides a stable connection that can effectively resist the functional forces exerted during mastication.
3. **Feasibility for Single-Visit Application:** The system allows for a relatively quick chairside adaptation, minimizing the need for multiple appointments and reducing treatment time.

By incorporating this attachment system, the overdenture is provided with enhanced stability, improved patient comfort, and increased longevity, making it a highly effective solution for prosthetic rehabilitation.

Conclusion

A tooth-supported overdenture using Rhein 83 castable attachments is a highly effective prosthodontic treatment that enhances denture retention, stability, and patient comfort. By utilizing remaining natural teeth as abutments, this approach helps preserve alveolar bone, improve chewing efficiency, and provide a more secure prosthesis compared to conventional complete dentures. Rhein 83 attachments offer a reliable and adaptable solution, allowing for long-term success with easy maintenance and repair options. However, careful case selection, proper oral hygiene, and regular follow-ups are essential to ensure the longevity of both the prosthesis and the abutment teeth.

Overall, this case series represents a functional, aesthetic, and cost-effective alternative to traditional dentures, improving the quality of life of patients.

References

1. Morrow RM, Powell JM, Jameson WS, Jewson CG, Rudd KD. Tooth supported complete dentures: an

- approach to preventive prosthodontics. *J Prosthet Dent.* 1969;21:513–522. doi: 10.1016/0022-3913(69)90073-0.
2. Bansal S, Aras MA, Chitre V. Tooth Supported Overdenture Retained with Custom Attachments: A Case Report. *J Indian Prosthodont Soc.* 2014 Dec;14(Suppl 1):283-6. doi: 10.1007/s13191-013-0340-0. Epub 2013 Dec 12. PMID: 26199532; PMCID: PMC4502008.
3. Leong JZ, Beh YH, Ho TK. Tooth-Supported Overdentures Revisited. *Cureus.* 2024 Jan 29;16(1):e53184. doi: 10.7759/cureus.53184. PMID: 38420101; PMCID: PMC10901637.
4. Jayasree K, Bharathi M, Nag VD, Vinod B: Precision attachment: retained overdenture. *J Indian Prosthodont Soc.* 2012, 12:59-62. 10.1007/s13191-011-0100-y
5. Stewart BL, Edwards RO. Retention and wear of precision-type attachments. *J Prosthet Dent.* 1983; 49:28–34. doi: 10.1016/0022-3913(83)90233-0.
6. Academy of Denture Prosthetics. Nomenclature Committee. Glossary of prosthodontic terms 10th edition. *Journal of Prosthetic Dentistry.*
7. Preiskel HW. Precision attachments in dentistry. In: Preiskel HW, editor. *Precision attachments in dentistry.* 3. London: Henry Kimpton; 1973. pp. 1–36.
8. Sharma HK, Padiyar N, Kaurani P, Singh DP, Meena S, Gupta A. Tooth-supported Overdenture using Castable Ball and Socket Attachments *Journal of Mahatma Gandhi University of Medical Sciences and Technology.* 2017 May;2(2):106-8.
9. Fenton AH. The decade of overdentures: 1970–1980. *J Prosthet Dent.* 1998; 79:31–36. doi: 10.1016/S0022-3913(98)70190-8.

10. Zarb GA, Jacob RF, Zarb JP: Overdentures. Prosthodontic treatment for edentulous patients (complete dentures and implant-supported prostheses). Mosby. 2004;160:176
11. Short-term quality of life change perceived by patients after transition to mandibular overdentures. *Braz Oral Res.* 2017, 31:e5. 10.1590/1807-3107bor-2017.vol31.0005