

## **GABA-B Receptor Autoimmune Encephalitis Presenting as Isolated Subacute Amnestic Syndrome: A Case Report and Review of Literature**

<sup>1</sup>Dr. Nasir Akber, <sup>3</sup>Dr. Omar Farooq, <sup>3</sup>Dr. Sobia Nisar, <sup>3</sup>Dr. Javaid Chachoo, <sup>2</sup>Dr. Shabir, <sup>2</sup>Dr. Suhail Para, <sup>2</sup>Dr. Kiran Zite, <sup>1</sup>Dr. Bhargavi, <sup>1</sup>Dr. Hemanyoun, <sup>1</sup>Dr. Suhail, <sup>1</sup>Dr. Sham Sul Haq, <sup>1</sup>Dr. Naisam, <sup>1</sup>Dr. Danish, <sup>1</sup>Dr. Asif, <sup>1</sup>Dr. Shahid, <sup>1</sup>Dr. Muzaffar, <sup>1</sup>Dr. Husain

<sup>1</sup>PGs, <sup>2</sup>Registrars, <sup>3</sup>Consultants, Department of General Medicine, Government Medical College and SSH, Srinagar

**Corresponding Author:** Dr. Omar Farooq, Professor, Neurologist, Department of General Medicine, Government Medical College and SSH, Srinagar.

**Citation this Article:** Dr. Nasir Akber, Dr. Omar Farooq, Dr. Sobia Nisar, Dr. Javaid Chachoo, Dr. Shabir, Dr. Suhail Para, Dr. Kiran Zite, Dr. Bhargavi, Dr. Hemanyoun, Dr. Suhail, Dr. Sham Sul Haq, Dr. Naisam, Dr. Danish, Dr. Asif, Dr. Shahid, Dr. Muzaffar, Dr. Husain, “GABA-B Receptor Autoimmune Encephalitis Presenting as Isolated Subacute Amnestic Syndrome: A Case Report and Review of Literature”, IJMSIR - November – 2025, Vol – 10, Issue - 6, P. No. 79 – 80.

**Type of Publication:** Case Report

**Conflicts of Interest:** Nil

### **Abstract**

**Background:** GABA-B receptor autoimmune encephalitis (GABA-B AE) is a rare limbic encephalitis subtype usually presenting with seizures, memory deficits, and strong paraneoplastic association. Seizure-negative forms are uncommon.

**Case:** A 55-year-old male presented with 20 days history of progressive anterograde amnesia and headache without seizures or psychiatric changes. MRI showed bilateral medial temporal hyperintensities. CSF revealed GABA-B receptor antibody positivity. CT chest/abdomen/pelvis showed bronchiolitis without malignancy. Treated with IV methylprednisolone with marked improvement in MMSE from 20→26 at 4 weeks.

**Conclusion:** GABA-B AE may present without seizures. Early immunotherapy improves clinical outcomes. Continuous malignancy surveillance is essential.

**Keywords:** GABA-B receptor; Autoimmune encephalitis; Limbic encephalitis; Memory impairment

### **Case Report**

A 55-year-old male (Patient Code: 2345678) presented with 20-day history of progressive forgetfulness affecting recent memory. Remote memory preserved. No fever, seizures, confusion, behavioral change, focal neurological deficits, or substance use. General physical examination was normal. MMSE was 20/27. Neurological exam: fully oriented, cranial nerves normal, normal gait and cerebellar function, no meningismus.

**MRI brain (3T, FLAIR + DWI):** bilateral medial temporal hyperintensity; mild left temporal expansion; no diffusion restriction; no contrast enhancement.

**CSF:** normal cell count, glucose, protein, viral panel negative; GABA-B receptor antibody positive.

**CECT chest/abdomen/pelvis:** Bronchiolitis; no tumor. Past history: Pheochromocytoma surgery 1 year prior.

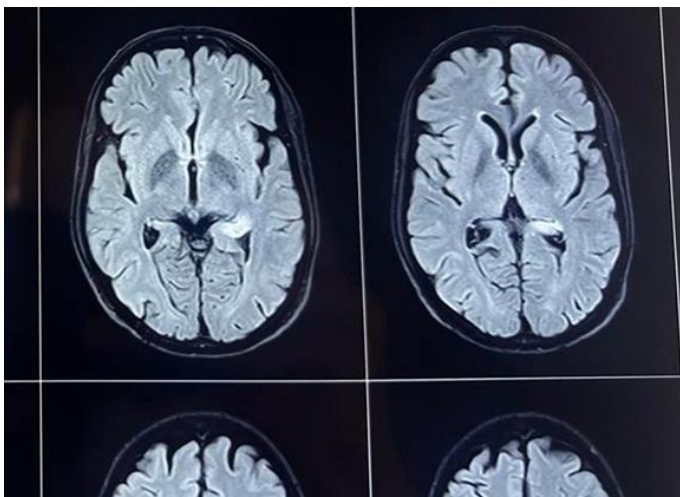
**Treatment:** IV methylprednisolone 1 g/day × 5 days.

**Outcome:** MMSE improved to 26/27 at 4-week follow-up. No seizures during course. Under periodic tumor surveillance

Figure 1: MRI axial images showing bilateral medial temporal hyperintensities on FLAIR sequence.

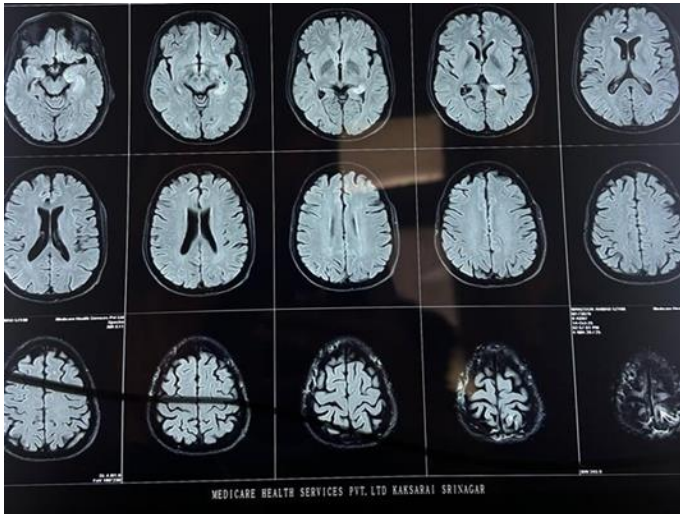

Figure 2: MRI axial DWI showing associated inflammatory changes without restriction, supporting autoimmune encephalitis diagnosis.



## Discussion

GABA-B AE commonly presents with refractory seizures; however, seizure-negative variants are rare (<10%). MRI abnormalities are typically mesial temporal predominant. Absence of restricted diffusion differentiates this from HSV encephalitis. Strong paraneoplastic link necessitates long-term tumor

screening.

Early steroid therapy in this patient resulted in significant cognitive recovery, indicating favorable prognosis in early-diagnosed immune-mediated phase.

## Conclusion

GABA-B AE should be considered in subacute amnesic syndromes with temporal lobe MRI abnormalities even in absence of seizures. Early immunotherapy improves outcomes. Tumor surveillance remains crucial.

## References

1. Lancaster E, Lai M, Peng X, et al. GABAB receptor autoantibodies in limbic encephalitis and lung cancer. *Neurology*. 2010.
2. Graus F, Titulaer MJ, et al. A clinical approach to diagnosis of autoimmune encephalitis. *Lancet Neurol*. 2016.
3. Höftberger R, Sabater L, et al. Encephalitis and GABAB receptors. *J Neurol Neurosurg Psychiatry*. 2013.
4. Maureille A, et al. Seizure-negative GABA-B encephalitis. *Epilepsia*. 2020.
5. Guan HZ, et al. Clinical analysis of 20 patients with anti-GABA-B receptor encephalitis. *BMC Neurol*. 2016.
6. Pittock SJ, et al. Autoimmune neurological paraneoplastic syndromes. *Continuum*. 2017.
7. Titulaer MJ, et al. Treatment outcomes in AE. *Neurology*. 2013.